



PATIENT

Monster Rios

PRESENTING CLINICAL SIGNS

History: Grade 4/6 heart murmur. Renal disease.

SPECIES

Feline

ECHOCARDIOGRAM FINDINGS

2D, m-mode, color flow and doppler imaging is available. The left ventricular wall is borderline normal in dimension. There is a diffusely hyperechoic endocardium consistent with fibrosis. The endocardium also appears mildly remodeled. The papillary muscles appear mildly remodeled. The left atrium is normal in size. The right atrium is normal in size. The right ventricle appears normal. The tricuspid valve appears normal in structure and mobility. No tricuspid regurgitation. The mitral valve is normal in structure and mobility. No mitral regurgitation. A dynamic RVOT obstruction is noted on color-flow and spectral imaging. Blood flow through the LVOT appears normal with no evidence of obstruction. Mild aortic insufficiency. No evidence of cardiac tumors or metastatic lesions on this scan.

BREED

Maine Coon

SEX

Male Neutered

AGE

14 years

CARDIAC CHART

WEIGHT

8.6lbs

FELINE CARDIAC PARAMETERS	BODY WEIGHT (kg)	HR (BPM)	IVSd (cm) (Moise, Pipers)	LVIDd (cm) (Moise, Pipers)	LVWd (cm) (Moise, Pipers)	FS (%)	EF (%)
NORMAL PARAMETER	-----	150-240	0.35-0.55	<2 (mean 1.5)	3.5-0.55	35-67	80-100
PATIENT	3.92	198	0.54	1.3	0.55	52	87
FELINE CARDIAC PARAMETERS	LA/AO (Boon)	LA/AO HEART BASE (Swe) (Abbott)	LA 2D short axis Base view (cm) (Abbott)	LVOT VEL (m/s)	RVOT VEL (m/s)	E max (m/s)	
NORMAL	<1.5	<1.3	<1.2	<1.6	<1.3	<0.9	
PATIENT	1.2	1.2	1.0	1.8	2.1	NM	
<p><i>*Note: All measurements based upon multi-modal images and methods. An average value is reported.</i> Adapted from June Boon, Veterinary Echocardiography, 1998 Abbott J & MacLean H JVIM 2006;20: 111-119, Moise et al. Am J Vet Res 47:1476, 1986. Pipers et al. Am J Vet Res 40:882, 1979.</p>							

INTERPRETED BY

Maggie Machen Lamy,
DVM DACVIM
(Cardiology)

IMAGING PERFORMED BY

Kelly Reschny, RVT

HOSPITAL NAME

Headon Forest
Animal Hospital

REFERRING VET

Dr. Wallace

INVOICE

25130

DATE

7/5/22

INTERPRETATION OF THE FINDINGS & FURTHER RECOMMENDATIONS

The only cause of a murmur identified is a suspect heart rate dependent flow obstruction through the right ventricle (DRVOTO), which is a physiologic finding (i.e., benign and of little clinical significance). This type of flow murmur will wax and wane secondary to tachycardia and volume changes. There is however a significant amount of LV remodeling and fibrosis with borderline wall dimensions, which may be indicative of early pathology or simply represent a normal variant. Regardless the left atrial dimension is normal, and there is minimal risk for complication at this time. Serial echocardiography will be necessary to determine progression and clinical relevance in the future. A small aortic leak is noted, and a **baseline blood pressure is recommended (particularly given azotemia).**

If needed, the risk for general anesthesia is low, however heart rate stimulating drugs such as atropine, glycopyrrolate or ketamine should be avoided unless medically necessary. Even without significant pathology, with this degree of remodeling and diastolic stiffening



PATIENT

Monster Rios

there is a mildly elevated risk for fluid overload in this patient. Judicious IV fluid use is recommended. Additionally, a screening blood pressure is recommended in any older cat prior to general anesthesia.

SPECIES

Feline

Given these findings, no medications are indicated at this time.

BREED

Maine Coon

Recommend recheck echocardiogram in 1 year to assess for progression or development of disease the pre-existing murmur may mask.

SEX

Male Neutered

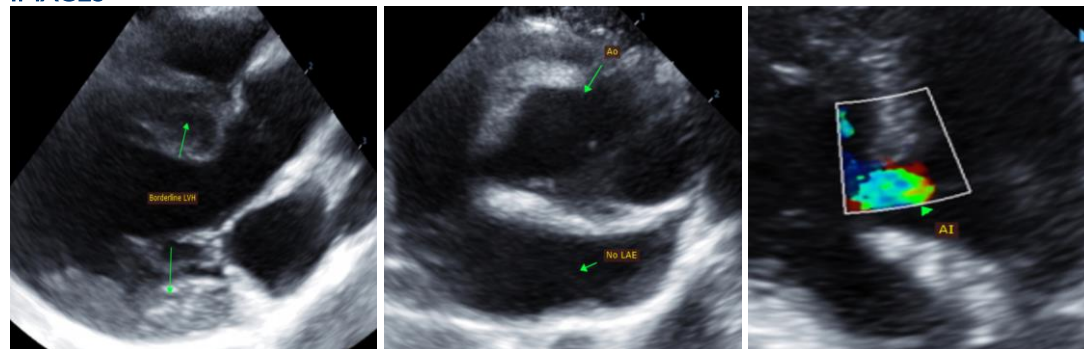
AGE

14 years

WEIGHT

8.6lbs

IMAGES



The information and recommendations provided are based on the images presented by the referring veterinarian. No evaluation can be communicated regarding pathology that was not visible in the image/video clips provided.

INTERPRETED BY

Maggie Machen Lamy,
DVM DACVIM
(Cardiology)

Thank you for this referral. This report was generated using transcription software, and minor dictation errors may be present. If the clinical or image interpretation does not parallel your findings or if I can be of any further assistance, please contact me.

Maggie Machen Lamy, DVM
Diplomate of the American College of Veterinary Internal Medicine (Cardiology)
info@sonopath.com

IMAGING PERFORMED BY

Kelly Reschny, RVT

HOSPITAL NAME

Headon Forest
Animal Hospital

REFERRING VET

Dr. Wallace

INVOICE

25130

DATE

7/5/22